



FUNGAL ENDOMETRITIS

Patrick M. McCue

DVM, PhD, Diplomate American College of Theriogenologists

An 11-year-old Quarter Horse mare presented to the Equine Reproduction Laboratory for a routine fall reproductive evaluation. The mare had been used successfully for several years as an embryo transfer donor, but had never carried a foal to term. She was noted to be in good physical condition and was in heat at the time of the evaluation. Ultrasound examination revealed active ovaries, mild endometrial edema and a very small amount of clear fluid in the uterine lumen. Culture of her uterus yielded moderate growth of the yeast *Candida albicans*. Evaluation of a uterine biopsy indicated chronic active superficial endometritis (Grade 2B). The cervix of the mare was noted to be moderately tight or closed, which is unusual for a mare in heat.

The mare was initially treated once daily during a 5-day period by uterine lavage (sterile saline plus vinegar or sterile saline alone) and infusion of an antifungal agent (fluconazole) into her uterus. The mare ovulated on the last day of treatment and was sent home. Prostaglandins were administered 7 days later and the mare returned for re-evaluation when she came back into estrus. A small amount of cloudy fluid was noted in the uterus on ultrasound examination and a culture of the uterus again yielded a moderate growth of yeast. A swab of the uterus for cytologic evaluation

revealed degenerated white blood cells and scattered yeast organisms. The yeast culture was sent to Cornell University for determination of antimicrobial sensitivity.

A therapeutic plan was developed and the mare was subsequently treated for 5 days during estrus by uterine lavage (sterile saline plus povidone-iodine solution) and daily intra-uterine administration of two antifungal agents (miconazole and nystatin) determined by sensitivity testing to be effective against this specific *Candida* organism. The mare eventually ovulated and was re-cultured when she returned to estrus. Thankfully, the uterus was free of yeast organisms. Unfortunately, the culture yielded a heavy growth of the bacterium *Streptococcus zooepidemicus*. This was treated with a 3-day course of intrauterine antibiotics (ticarcillin).

With some trepidation, another recheck evaluation was performed in late November. Only a trace amount of clear fluid was observed during the ultrasound examination, no inflammatory cells were noted on cytology, and no evidence of yeast or *Streptococcus* bacteria was present on culture.

The mare was housed under lights from December 1 through March, and the mare began to cycle in mid-February. She was

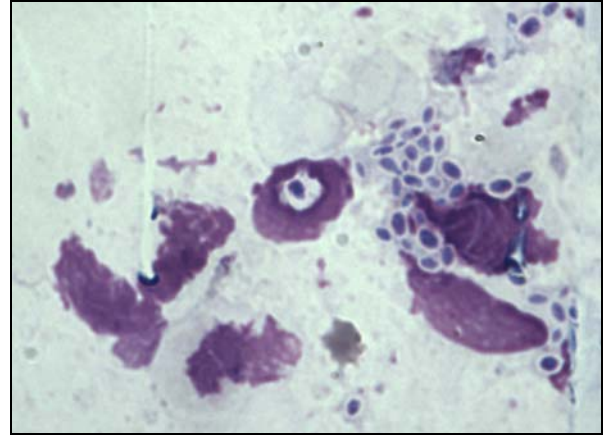
bred with shipped-cooled semen in the third week of February and the first embryo flush of the year was negative. The mare was re-bred to the same stallion when she came back into heat and this time an embryo was collected and successfully transferred into a recipient mare.

She has since been bred with frozen-thawed semen from a second stallion and the goal is to let her carry this pregnancy to term.

Take home message(s):

1. Intrauterine yeast infections can be very difficult to resolve. Aggressive therapy, attention to detail, and perseverance are required to be successful.
2. Ideally, determination of the antifungal medication(s) to use should be based on antimicrobial sensitivity testing.
3. It is not unusual to have a bacterial infection in conjunction with a yeast infection.

It is my opinion that a mare should be allowed to carry her own foal to term by the time she is 8 to 10 years of age and should carry a foal to term every 3 to 4 years, if possible. This should help to maintain normal uterine and cervical function.



Yeast organisms on uterine cytology