



## EMBRYO EVALUATION

Patrick M. McCue

DVM, PhD, Diplomate American College of Theriogenologists

Embryos are routinely evaluated after collection and prior to transfer into a recipient mare. The evaluation usually takes only a few moments to perform and can provide valuable information as to the probability that a given embryo may survive after transfer. The primary goal is to determine embryo quality, but the evaluation may also identify embryos with significant abnormalities, differentiate unfertilized oocytes from small embryos, and determine if the developmental stage is consistent with embryo age.

Morphologic assessment of an embryo includes evaluation of developmental stage and structural features such as embryo size and shape, presence of extruded or degenerated cells, color characteristics, number and compactness of the cells or blastomeres that comprise the early embryo, integrity of the zona pellucida and presence or absence of a capsule. These characteristics are summarized and the embryo is assigned a numeric grade that corresponds with overall embryo health.

The *developmental stage* of an embryo is normally directly related to age or the number of days after ovulation. After fertilization, a series of cleavage divisions yields an embryo with multiple individual cells called blastomeres. A morula is an embryo with  $\geq 32$  tightly compacted

blastomeres surrounded by a thick zona pellucida. An equine embryo is usually at the morula stage of development when it first enters the uterus approximately 6 days after ovulation.

As embryonic development continues, the morula transitions into a blastocyst as cell divisions proceed and a small fluid filled cavity or blastocoele begins to form within the center of the embryo. The blastocyst consists of two populations of cells – an outer rim of trophoblast cells and a distinct inner cell mass embedded within the wall of trophoblast cells. The trophoblast layer will eventually form the placenta and the inner cell mass will form the embryo proper.

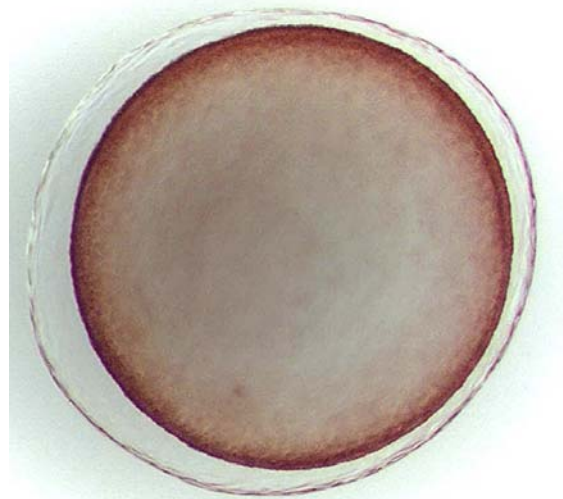
The *size* of an embryo is also typically related to the age of the embryo. A day 6 equine embryo is approximately 0.2 mm in diameter, while day 7, 8 and 9 embryos are about 0.4, 1.1 and 2.2 mm in diameter, respectively. As the embryo expands, the zona pellucida becomes thinner and eventually is lost. A thin, transparent membrane called the capsule forms under the zona pellucida and becomes visible in the expanding embryo after the zona pellucida is lost. The rapid increase in size is clinically significant, as only small embryos (<0.3 mm) are suitable for freezing and large expanded blastocysts (>1.5 mm)

are more easily damaged during flushing, washing and transfer procedures.

*Grade* refers to the quality score of an embryo. A scoring system has been developed that ranges from 1 to 5. A grade 1 embryo is considered excellent, with a spherical shape, and cells of uniform size, color and texture. Grade 2 embryos are considered good, with minor imperfections such as a few extruded blastomeres and irregular shape. A grade 3 embryo is considered fair, with moderate problems such as extruded blastomeres, degenerate cells, or a collapsed blastocoele. Grade 4 embryos are considered poor, with severe problems including collapsed blastocoele, numerous extruded blastomeres and degenerate cells, but with an inner cell mass that still appears to be viable. A grade 5 embryo would be totally degenerated or dead. Embryos should be graded relative to their developmental stage (i.e. characteristics of a normal grade 1 morula are different from a normal grade 1 expanded blastocyst).

It is important to differentiate embryos from unfertilized oocytes. Unfertilized oocytes are normally retained within the oviduct, but occasionally are recovered during an embryo flush procedure. Passage of an unfertilized oocyte through the uterotubular junction and into the uterus most commonly occurs in the presence of a viable embryo. Unfertilized oocytes are small (<0.2 mm), oval in shape and flattened. The cytoplasm within the one-celled oocyte can have a granular or fragmented appearance as it degenerates, which may resemble blastomeres of a morula stage embryo. The easiest way to differentiate an embryo from an unfertilized oocyte is that an embryo is spherical and can roll across the bottom of a Petri dish when examined, while an unfertilized oocyte is flat and cannot roll.

Pregnancy rates in recipient mares are correlated with the grade or quality score of the embryo prior to transfer. Grade 1 and 2 embryos have approximately the same transfer success rate, whereas Grade 3 and 4 embryos have significantly lower initial pregnancy rates after transfer and a higher incidence of embryonic loss if a pregnancy is initially established.



**Photograph of an expanded blastocyst-stage embryo**