



PLACENTA EVALUATION

Patrick M. McCue

DVM, PhD, Diplomate American College of Theriogenologists

The placenta is the connection between the developing fetus and the mare and provides the means for obtaining nutrition and for gas exchange. Examination of the placenta can offer valuable insight into the health of the newborn foal. Consequently, it is recommended that owners, farm managers or foaling attendants perform an evaluation of each placenta.

The placenta is normally passed within three hours after foaling. Once passed, the placenta should be immediately removed from the foaling area and rinsed free of gross debris. Disposable plastic or latex gloves should be worn during handling and examination. If possible, the weight of the placenta should be determined. An inexpensive bathroom scale is sufficient. Under normal circumstances, the weight of the placenta will be approximately 11% of the body weight of the foal. An increased weight may be the result of edema associated with factors such as fescue toxicosis or may be due to an infectious condition such as placentitis. Both conditions may be associated with a medically compromised fetus.

The placenta consists of three primary components, the outer placental membrane or chorioallantois, the inner placental membrane or amnion, and the umbilical cord. In a normal foaling, the thicker outer

placental membrane is almost always turned inside-out as the placenta is passed.

For examination, the outer placental membrane should be turned right-side out and then spread out on a clean flat surface. The allantoic (side toward the foal) surface is smooth and pink and blood vessels are visible coursing along its surface. The chorionic (side toward the uterus) surface has a brick-red velvety appearance due to the presence of structures known as microcotyledons. Microcotyledons are the microscopic villi or finger-like projections that provide the 'Velcro-like' attachment of the placenta to the uterine lining.

The membranes may be laid out with the chorioallantois in an "F" or "Y" shape, with the two horns of the placenta forming the arms of the "F" or "Y" and the body of the placenta forming the base. The umbilical cord and amnion should protrude from the base or body of the placenta.

One of the first things that may be noted is that the tips of the placental horns differ significantly in size and thickness. The larger horn housed the fetus and is referred to as the pregnant horn. The tip of the pregnant horn is always thicker than the tip of the smaller (non-pregnant horn).

The placenta should be examined to determine if it was passed intact or if a piece

is missing and potentially still inside the mare. By far the most likely portion of the placenta that may be retained is the thin tip of the non-pregnant horn. Retention of even a small piece of placenta in the uterus poses a serious threat to the health of the mare.

The area of the body of the placenta that was in direct contact with the cervix of the mare will be pale in color and devoid of the red velvety microcotyledons. This area is referred to as the 'cervical star' region of the chorionic surface of the placenta. Ascending bacterial infections that pass through the cervix may result in thickening or the presence of a mucus-like exudate in the area around the cervical star. If a placental infection is present, the foal may have been exposed to pathogenic microorganisms prior to being born and should be considered high-risk for medical complications.

The thin, white amnion should be examined next. The primary abnormality that may be noted in the amnion is a yellow-orange discoloration due to meconium staining. Stress to the fetus prior to birth may result in premature passage of fecal material (meconium). Meconium staining may be an early warning sign that the foal is compromised. In addition, affected foals may aspirate meconium into their lungs and develop serious respiratory complications.

The umbilical cord will virtually always have a mild to moderate degree of twisting present. Excessive twisting of the cord can result in decreased blood flow from the placenta to the fetus and other problems.

Evaluation of the placenta is a valuable procedure that can positively impact health and welfare of both the newborn foal and the mare. It is recommended that your veterinarian be contacted for an initial lesson in field evaluation of the placenta and that he or she be notified if abnormalities are identified in subsequent placental examinations.

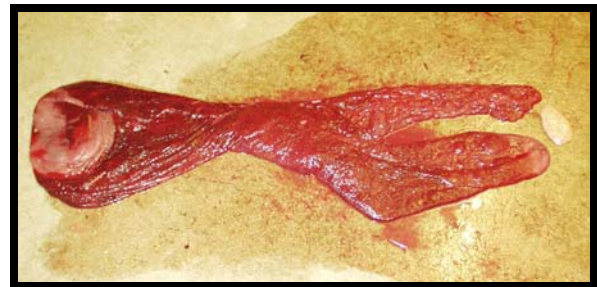


Photo of an equine placenta