



SPERM INJECTION

Patrick M. McCue

DVM, PhD, Diplomate American College of Theriogenologists

Embryo transfer (ET) is a technique that can be successful if the donor mare can grow and ovulate a follicle, has a patent and functional oviduct, and the uterine environment is healthy enough to sustain an embryo for a few days prior to collection. Oocyte transfer (OT), discussed last month, is valuable when the donor mare is not able to ovulate a large follicle, if oviductal or uterine abnormalities are present, and if the number of normal motile spermatozoa is not a limiting factor.

Intracytoplasmic sperm injection (ICSI) is an advanced reproductive procedure that may be beneficial in selected cases in which the number of spermatozoa available is very limited. Examples may include stallions with extremely low numbers of normal motile spermatozoa in their ejaculate or when only a few straws of frozen semen exist. It may also be used when trying to obtain pregnancies from oocytes (eggs) collected from ovaries removed from a mare after euthanasia.

The initial procedure in the ICSI program is collection of an oocyte from a pre-ovulatory follicle. The harvested oocyte may be cultured in an incubator for several hours to allow for further maturation in vitro. Injection of a single sperm into the oocyte is accomplished by a trained technician using a specialized microscope and a device called a

micromanipulator. A single spermatozoon is aspirated into the tip of a fine sharp glass injection needle or micropipette. The oocyte is held in place by a small amount of suction applied to another fine rounded glass pipette. The injection pipette is inserted through the zona pellucida that surrounds the oocyte and the sperm is injected directly into the cytoplasm of the oocyte.

The injected oocyte may be transferred immediately into the oviduct of a recipient mare or may be returned to the incubator and cultured for an additional 24 to 48 hours. If the oocyte was successfully fertilized, the single-celled oocyte should cleave into two cells and then those cells should cleave again into 4 cells, etc. over the next few days. The cleaved embryo would then be surgically transferred into the oviduct of a synchronized recipient mare. As in vitro culture systems become more efficient and successful, it will be common to culture developing ICSI derived embryos for 5 to 7 days until they can be transferred directly into the uterus of a recipient mare by a traditional non-surgical technique.

The first foal produced from ICSI was born in 1996 at Colorado State University. Currently, sperm injection is only available at a few equine reproduction referral centers. The technique involves specialized equipment and requires

advanced training by clinicians and/or technical staff.

Sperm injection should be considered when faced with a situation in which only 1 or 2 straws of frozen semen remain from a stallion that is no longer alive or additional semen cannot be collected. Sperm injection could theoretically be used to produce multiple foals from a single straw of semen. For example, a small piece of the frozen straw could be snipped off under liquid nitrogen and thawed, while the rest of the straw remained frozen (i.e. a 'cut-straw' approach). Alternatively, the entire straw could be thawed and the contents diluted in additional semen extender and refrozen in many smaller straws (i.e. a 'refrozen semen approach'). In either situation, the overall principle is conservation and achievement of maximum use of a limited number of spermatozoa from a valuable stallion.

Sperm injection bypasses the requirement for a spermatozoon to bind to and penetrate the zona pellucida of the oocyte. This has historically been a road block to the success of traditional in vitro fertilization (IVF) in the horse. As a consequence, 'mechanical fertilization' by sperm injection currently has a better prognosis as a means of producing in vitro pregnancies in the horse than traditional IVF techniques that work well in other species, such as cattle and sheep.

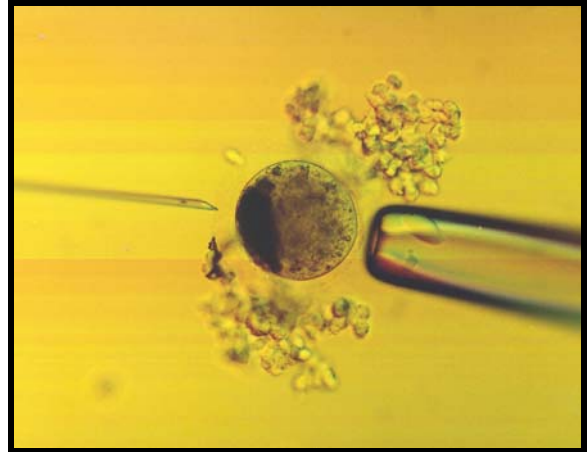


Photo of sperm injection