



RUPTURED BLADDER – The Foal was “Not Quite Right”

Patrick M. McCue

DVM, PhD, Diplomate American College of Theriogenologists

We watched as a 16-year-old mare gave birth unassisted at 1:15 in the morning one day prior to her due date in mid-April. She had given birth to 6 healthy foals previously.

The navel of the newborn filly was immediately dipped with diluted chlorhexadine solution after the umbilical cord broke and the stump was subsequently dipped 3 times per day for the next 2 days. She passed meconium within an hour and a half and first nursed from the mare within 2 hours after birth.

Colostrum collected from the mare was estimated to have a high antibody content based on both specific gravity and brix refractometer scores. A blood sample collected from the foal at 16 hours of age revealed an IgG antibody level of >800 mg/dl, which was considered adequate for immune protection against infectious diseases.

Throughout the next 4 days, the foal was generally noted to be alert and active in her stall and to nurse regularly from her dam. The filly was also observed to urinate and defecate normally during this time period. However, there were also occasional reports of the foal being ‘not quite right’. Barn personnel would occasionally catch her posturing as if to urinate or defecate and nothing would pass. She would then

straighten up and meander around her stall as if nothing was wrong.

An emergency call was received at 6:00 am on day 6 after foaling, when the foal was discovered to be depressed and reluctant to move. A quick physical examination revealed that her body temperature was increased to 103.9°F and mild inflammatory reaction was noted around the lining of the eyes (conjunctivitis). The external umbilical stump was not swollen, not damp, and did not have a discharge. Her joints were not swollen or painful upon manipulation.

A list of potential medical problems was formulated and a series of diagnostic tests immediately performed to help rule in or rule out various potential complications. A complete blood count (CBC) revealed an elevation in the number of white blood cells, suggesting an inflammatory or infections condition. Blood chemistry tests showed high levels of blood urea nitrogen (BUN) and creatinine, indicating issues with the urinary system; electrolyte analysis revealed that serum concentrations of sodium and chloride were low and potassium levels were elevated.

The combined test results strongly suggested that the young filly had ruptured her urinary bladder. An ultrasound examination of the abdomen was quickly performed. The exam clearly showed a large volume of free fluid

in her abdomen along with a small urinary bladder.

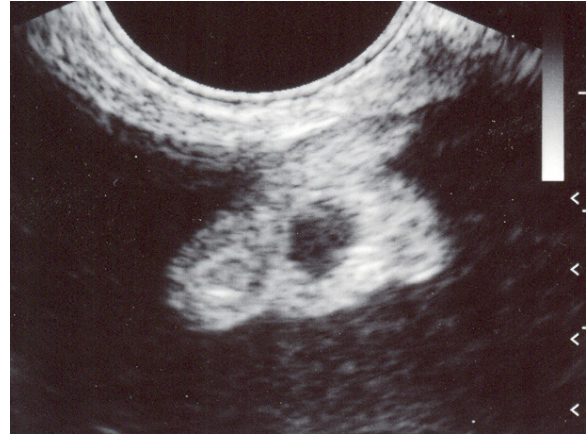
An area on her ventral abdomen was shaved and scrubbed clean with disinfectant. A small needle was passed into the abdomen and a stream of pale yellow fluid rapidly exited the needle. The ultrasound and abdominal fluid analysis confirmed the original diagnosis of a ruptured bladder.

The mare and filly were transported to the Veterinary Teaching Hospital for surgery. Exploration of the abdomen revealed a 1 inch tear in the dorsal wall of the urinary bladder which was successfully repaired. The foal recovered uneventfully and was sent home 2 days later.

Rupture of the urinary bladder is a potentially life-threatening condition in newborn foals. An early diagnosis and surgical intervention are required for a successful outcome.

Take home messages:

1. Ruptured bladder is not uncommon in foals.
2. The incidence rate is equal in colts and fillies.
3. Rupture does not always occur at birth.
4. Abdominal ultrasonography and serum chemistry are the diagnostic tests of choice.



Ultrasound photograph of fluid-filled abdomen in the foal with the ruptured bladder